ORIGINAL ARTICLE

Induction Chemotherapy for Advanced Squamous Cell Carcinoma of the Paranasal Sinuses

Ehab Y. Hanna, MD; Alvaro Diaz Cardenas, MD; Franco DeMonte, MD; Dianna Roberts, PhD; Michael Kupferman, MD; Randal Weber, MD; David Rosenthal, MD; Merrill Kies, MD

Objective: To review the oncologic outcomes in patients with advanced (stage III-IV) squamous cell carcinoma of the paranasal sinuses treated with induction chemotherapy prior to definitive local therapy.

Methods: The medical records of 46 consecutive patients with previously untreated, biopsy-proved squamous cell carcinoma of the paranasal sinuses who received induction chemotherapy during the course of their treatment were reviewed for demographics, tumor types and stages, treatment details, and oncologic outcomes.

Results: Of the 46 patients (median age, 59 years), the tumor epicenter was in the maxillary sinus in 31 (67%), ethmoid sinus in 9 (20%), nasal cavity in 4 (9%), and sphenoid sinus in 2 (4%). All patients had T3 or T4 tumors, and 12 (26%) patients had clinical evidence of nodal metastasis, with an overall stage of III (20%) or IV (80%). Induction chemotherapy regimens consisted of a combination of a taxane and platinum in 80% of patients, by themselves (14 patients) or in combination with a third agent, such as ifosfamide (14 patients) or 5-fluorouracil (9 patients). The combination of a taxane and 5-fluorouracil was used in the remaining 9 patients. More than two-thirds (67%) of the patients achieved at least a partial response to induction chemotherapy, 24% had progressive disease, and 9% had stable disease. Subsequent treatment after induction chemotherapy consisted of surgery, usually followed by radiation or chemoradiation or by definitive radiation or chemoradiation with surgical salvage of any residual disease. Overall, surgical resection was performed in only 24 of 46 patients (52%) treated with induction chemotherapy. The 2-year survival for patients with at least a partial response or stable disease after induction chemotherapy was 77% in contrast to only 36% for patients with progressive disease.

Conclusions: Tumor response to induction chemotherapy in patients with advanced squamous cell carcinoma of the paranasal sinuses may be predictive of treatment outcome and prognosis. Favorable response to induction chemotherapy is associated with better survival and a reasonable chance of organ preservation.

Arch Otolaryngol Head Neck Surg. 2011;137(1):78-81

Author Affiliations: Division of Skull Base Surgery, Department of Head and Neck Surgery, Head and Neck Center (Drs Hanna, Cardenas, DeMonte, Roberts, Kupferman, and Weber), and Departments of Head and Neck Radiation Oncology (Dr Rosenthal) and Thoracic Medical Oncology (Dr Kies), The University of Texas MD Anderson Cancer Center, Houston, Texas.

Treatment of cancers of the paranasal sinuses (PNS) is challenging because of the relative infrequency of those cancers, heterogeneous histologic characteristics and biologic behavior, advanced stage at presentation, and proximity to vital structures such as the orbit, skull base, and brain.

Currently, standard therapy for patients with advanced cancer of the PNS includes surgery and adjuvant radiotherapy. Radical surgical excisions such as craniofacial resection, total maxillectomy, or orbital exenteration result in significant morbidity.[1] Despite radical surgery and postoperative high-dose radiation, less than half the patients survive for more than 5 years. A systematic review of 154 articles published from 1960 to 1998 regarding the treatment results of 16 396 patients with carcinoma of the PNS and minimal follow-up of longer than 2 years showed an overall survival rate of 41% and 2-year local disease control rate of 60%.[2] These results have not changed significantly in the last 2 decades (**Table**).[3-11] Local recurrence at the primary site and distant metastasis are the most common patterns of treatment failure. There is a need for more effective, less morbid treatment of patients with advanced cancer of the PNS. Strategies to improve treatment outcome should therefore focus on improving local disease control and reducing distant metastasis. The incorporation of neoadjuvant chemotherapy in the multimodality treatment of advanced cancers of the PNS has shown some promise in this regard.[12-17] The purpose of this study

©2011 American Medical Association. All rights reserved.
Downloaded From: http://archotol.jamanetwork.com/ on 05/19/2013

Table. Outcome of Patients With Advanced Cancer of the PNS Treated With Combined Surgery and Radiotherapy

Source	Patients, No.	%		
		5-Year Survival	Local Recurrence	Distant Metastasis
Lavertu et al,[3] 1989	54	38	52	NA
Spiro et al,[4] 1989	105	38	49	15
Zaharia et al,[5] 1989	149	36	43	NA
Paulino et al,[6] 1998	48	47	46	17
Le et al,[7] 1999	97	34	54	34
Myers et al,[8] 2002	141	52	56	33
Ganly et al,[9] 2005	334	48	NA	NA
Guntinas-Lichius et al,[10] 2007	229	41	36	NA
Snyers et al,[11] 2009	76	42	36	NA

Abbreviations: NA, not applicable; PNS, paranasal sinuses.

was to review the outcomes of treatment for patients with advanced (stage III-IV) squamous cell carcinoma (SCC) of the PNS treated in The University of Texas MD Anderson Cancer Center with induction chemotherapy prior to definitive local therapy.

METHODS

Forty-six consecutive patients with previously untreated, biopsy-proved advanced (T3-T4) SCC of the PNS who received induction chemotherapy during the course of their treatment at The University of Texas MD Anderson Cancer Center were included in this study. Medical records were reviewed for patient demographics, tumor types and stages, treatment details, and oncologic outcomes. The study was approved by the institutional review board. Main outcome measures included response to induction chemotherapy, survival, and disease recurrence. Descriptive statistics for scaled values and frequencies of study patients within the categories for each of the outcomes of interest were enumerated with use of commercial statistical software Statistica (StatSoft, Inc, Tulsa, Oklahoma) and SPSS (SPSS for Windows, SPSS Inc, Chicago, Illinois). Correlations between outcomes and end points were assessed by the Pearson χ^2 test or, when there were fewer than 10 patients in any cell of a 2×2 grid, by the 2-tailed Fisher exact test. Curves describing overall and disease-specific survival were generated by the Kaplan-Meier product limit method. The statistical significance of differences between the actuarial curves was analyzed via the log-rank test. Follow-up time was considered the time from first appointment at The University of Texas MD Anderson Cancer Center for the primary tumor of concern until the date of last contact or death for survival measurements and from the end of treatment for the original disease to first recurrence for measurements of disease-free intervals.

RESULTS

Of the 46 patients (median age, 59 years), the tumor epicenter was in the maxillary sinus in 31 (67%), the ethmoid sinus in 9 (20%), the nasal cavity in 4 (9%), and the sphenoid sinus in 2 (4%). All patients had T3 (9 patients) or T4 tumors (37 patients; 25 with T4a and 12 with T4b), and 12 patients (26%) had clinical evidence of nodal metastasis with an overall stage of III (9 patients [20%]) or IV (37 patients [80%]). Induction chemotherapy regimens consisted of a combination of a taxane and platinum in 80% of patients, by themselves (14 patients) or in combination with a third agent, such as ifosfamide (14 patients) or 5-fluorouracil (9 patients). The combination of a taxane and 5-fluorouracil was used in the remaining 9 patients. Of the 46 patients, 31 achieved at least a partial response (67%) to induction chemotherapy, 4 patients had stable disease (9%), and 11 had progressive disease (24%). Subsequent treatment after induction chemotherapy consisted of surgery (22 patients), usually followed by postoperative radiation (n=15) or chemoradiation (n=5) or with definitive radiation (n=14) or chemoradiation (n=8) with planned surgical resection for any residual disease (n=2). Two patients with initially unresectable (T4b) disease that showed progression after induction chemotherapy refused further therapy. Overall, surgical resection was performed in 24 of 46 patients (52%) treated with induction chemotherapy. Mean follow-up for all patients was 36 months.

Disease recurrence occurred in 7 of 46 patients (15%). The first site of recurrence was local in 4 patients, local and distant in 1 patient, regional in 1 patient, and distant in 1 patient. The 2-year overall survival for all patients treated with induction chemotherapy as part of their multimodality treatment plan was 67%. The 2-year survival for patients with at least a partial response or stable disease after induction chemotherapy was 77% in contrast to only 36% for patients with progressive disease ($P=.05$). Similarly, disease-specific survival was significantly different ($P=.008$) in patients who had response to or stable disease with induction chemotherapy compared with those who had progressive disease (**Figure**).

COMMENT

Few studies[12-17] have investigated the role of neoadjuvant chemotherapy in the management of advanced cancer of the PNS. One of the earliest reports included an analysis of 16 patients with previously untreated advanced cancer of the PNS who received chemotherapy as part of their initial therapy.[12] Six of these patients had metastatic disease at the start of treatment (4 to the central nervous system and 2 to the lung). Most patients (78%) had SCC. All patients underwent surgery and/or radiotherapy after induction chemotherapy. The overall response rate to chemotherapy was 82% (complete response, 44%; partial response, 38%). The median sur-

©2011 American Medical Association. All rights reserved.
Downloaded From: http://archotol.jamanetwork.com/ on 05/19/2013

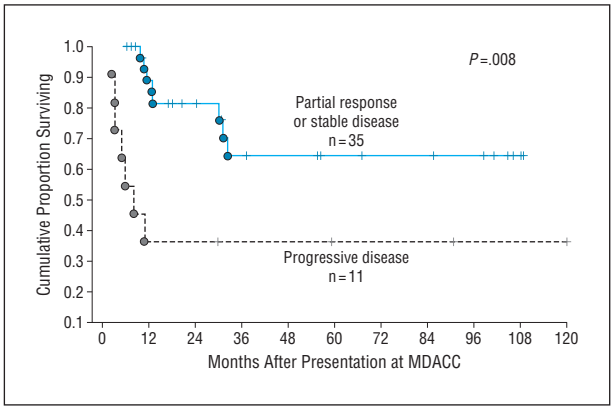

Figure. Disease-specific survival in patients with advanced squamous cell carcinoma of the paranasal sinuses according to response to induction chemotherapy. MDACC indicates The University of Texas MD Anderson Cancer Center; open circle, died of disease; and plus sign, last contact.

vival, based on response to chemotherapy, was as follows: complete response, 21 months (range, 10-81 months), partial response, 14 months (range, 2-21 months), and no response, 3 months (range, 1-7 months). Similar to the findings in the study reported here, the results of their study suggest that patients with cancer of the PNS are responsive to induction chemotherapy and that tumor response to neoadjuvant chemotherapy may be predictive of survival (Figure). Interestingly, the observed improved survival in patients who responded to induction chemotherapy in our study seems to be independent of their subsequent definitive local therapy. With a mean follow-up of 36 months, 24 of 35 (69%) of these patients were alive, and this survival rate and locoregional disease control were not significantly different whether they had surgery (n=17) or definitive radiation or chemoradiation with curative intent. In contrast, only 1 of the 11 patients with progressive disease after induction chemotherapy was alive at last contact, regardless of subsequent local therapy.

In 1989, a preliminary report from The University of Texas MD Anderson Cancer Center demonstrated that repeated superselective intra-arterial chemotherapy was feasible in patients with advanced cancer of the PNS and that radical craniofacial surgery was avoided in approximately one-third of the patients because of complete or near-complete response to chemotherapy.[13] A more recent study from The University of Texas MD Anderson Cancer Center reported the efficacy, organ-preservation rate, and safety of intra-arterial cisplatin in combination with intravenous paclitaxel and ifosfamide in patients with locally advanced carcinoma of the PNS who required orbital exenteration or major craniofacial resection for complete tumor resection.[17] Evaluable patients who received at least 1 course of intra-arterial cisplatin (n=19) had an overall response rate of 58% (complete response, 26%; partial response, 32%). Locoregional treatment after induction chemotherapy included radiation, surgery, surgery plus postoperative radiation, and concurrent chemoradiation. At the completion of treatment, 14 of 23 patients (61%) with locally advanced disease were disease free, and the orbit was preserved in 21 of 24 patients (88%). The overall survival, progression-free survival, and disease-free survival at 2 years were 60%, 50%, and 84%, respectively. Toxicity was substantial, with 2 patients experiencing cerebrovascular ischemia (1 transient and 1 cerebrovascular accident) and 3 patients experiencing cranial neuropathy, which was reversible in 2 of these patients. These results suggest that despite the encouraging organ-preservation rate, the intra-arterial route of administration of chemotherapy resulted in substantial toxicity, especially of the neurologic type. Similar efficacy of induction chemotherapy was reported with the more standard intravenous route of administration in patients with advanced cancer of the PNS.[14-16]

Another approach, popularized by Samant and colleagues,[18] consists of 3 to 4 weekly infusions of intra-arterial cisplatin (150 mg/m^2 per week) and systemic sodium thiosulfate neutralization with concurrent preoperative radiotherapy (2.0 Gy/fraction per day) limited to a total dose of 50 Gy in 5 weeks to minimize complications, followed by planned surgery performed approximately 8 weeks after completion of radiotherapy. After a median follow-up of 53 months in 19 patients treated with this regimen, rates of actuarial overall survival at 2 and 5 years were 68% and 53%, respectively. The investigators concluded that despite the advanced stage and unfavorable nature of cancer in their cohort, the results indicate that this regimen holds promise and merits further study. In 2009, Homma et al[19] reported on the use of intra-arterial cisplatin with concurrent radiation for the definitive treatment of sinonasal cancer without any dose reduction of radiotherapy (65-70 Gy), with surgery reserved for salvage of persistent disease. In their study of 47 patients with a median follow-up of 4.6 years, the estimated 5-year local progression-free and overall survival were 78.4% and 69.3%, respectively. There were no treatment-related deaths. Osteonecrosis occurred in 7 patients and brain necrosis occurred in 2 patients. Sixteen patients developed ocular and visual problems as late adverse affects.

Excellent long-term local control, overall survival, and disease-free survival were reported in 19 patients with locoregionally advanced (stage III and IV) cancer of the PNS who received treatment at The University of Chicago with a multimodality therapy incorporating induction chemotherapy followed by surgery and postoperative concurrent chemoradiotherapy.[16] Induction chemotherapy achieved a clinical response in 87% of the patients, and a complete histologic response was documented at the time of surgery in half these patients. The overall survival at 5 and 10 years was 73% and 54%, respectively, and the disease-free survival at 5 and 10 years were each 67%. Local control at 5 and 10 years was 76% each. Regional and distant failures were unusual, with a 10-year regional control rate of 93% and a distant control rate of 96%.

The results of these studies are encouraging, and the techniques described herein may be superior to those achieved with surgery and radiotherapy. In the study reported here, the relatively high survival rates of the entire patient cohort, particularly of those who showed response to induction chemotherapy, are promising given that most patients (80%) had stage IV disease. In a study of 109 patients with cancer of the PNS treated with sur-

©2011 American Medical Association. All rights reserved.
Downloaded From: http://archotol.jamanetwork.com/ on 05/19/2013

gery and/or radiation reported in 2009 by Mendenhall and colleagues,[20] the 5-year overall survival rates were 71% for stages I to III disease but only 45% for stage IV disease.

Also of note in the study reported herein is the relatively high number (37 of 46) of T4 tumors, with high prevalence of orbital (n=31) and skull base (n=14) invasion. Despite this locally aggressive disease, orbital preservation was feasible in all but 6 patients, local recurrence rate was low, and local disease control was high.

This study has some limitations. Owing to the retrospective design, the specific factors that prompted the use of induction chemotherapy in these patients are not known. Induction chemotherapy may have been considered in patients who were not good surgical candidates because they had unresectable tumors, were not fit for surgery, or had refused radical surgery. Other possible factors include recommendation of neoadjuvant chemotherapy by the treating physician for advanced disease to enhance the chances of orbital preservation or to reduce the risk of distant metastasis. Similarly, the exact factors that guided the decision to treat patients with surgery or radiation after induction chemotherapy are not known. It is likely that patients who were deemed to be good surgical candidates by the treating physician underwent surgery and those who were not underwent chemoradiation.

Despite these limitations, the results of this study suggest that incorporation of neoadjuvant chemotherapy into the multimodal treatment of patients with advanced SCC of the PNS is promising and may improve treatment outcomes. A relatively high number of patients with advanced SCC of the PNS show response to neoadjuvant chemotherapy, and tumor response may be predictive of treatment outcome and prognosis. Favorable response to induction chemotherapy may be associated with better survival and a reasonable chance of organ preservation. Further study of the role of neoadjuvant chemotherapy in patients with SCC of the PNS is warranted.

Submitted for Publication: April 1, 2010; final revision received August 26, 2010; accepted October 11, 2010.
Correspondence: Ehab Y. Hanna, MD, FACS, Division of Skull Base Surgery, Department of Head and Neck Surgery, Head and Neck Center, The University of Texas MD Anderson Cancer Center, 1400 Pressler St, Houston, TX 77030 (eyhanna@mdanderson.org).
Author Contributions: Drs Hanna and Weber had full access to all the data in the study and take responsibility for the integrity of the data and the accuracy of the data analysis. *Study concept and design:* Hanna, DeMonte, and Kupferman. *Acquisition of data:* Hanna, Cardenas, and Rosenthal. *Analysis and interpretation of data:* Hanna, Cardenas, Roberts, Kupferman, Rosenthal, Weber, and Kies. *Drafting of the manuscript:* Hanna and Cardenas. *Critical revision of the manuscript for important intellectual content:* Hanna, DeMonte, Roberts, Kupferman, Weber, Rosenthal, and Kies. *Statistical analysis:* Roberts. *Obtained funding:* Hanna. *Administrative, technical, and material support:* Hanna, DeMonte, and Kupferman. *Study supervision:* Hanna and Rosenthal.
Financial Disclosure: None reported.
Previous Presentation: This study was presented at the American Head and Neck Society Annual Meeting; May 30 and 31, 2009; Phoenix, Arizona.

REFERENCES

1. Ganly I, Patel SG, Singh B, et al. Complications of craniofacial resection for malignant tumors of the skull base: report of an International Collaborative Study. *Head Neck*. 2005;27(6):445-451.
2. Dulguerov P, Jacobsen MS, Allal AS, Lehmann W, Calcaterra T. Nasal and paranasal sinus carcinoma: are we making progress? A series of 220 patients and a systematic review. *Cancer*. 2001;92(12):3012-3029.
3. Lavertu P, Roberts JK, Kraus DH, et al. Squamous cell carcinoma of the paranasal sinuses: the Cleveland Clinic experience 1977-1986. *Laryngoscope*. 1989; 99(11):1130-1136.
4. Spiro JD, Soo KC, Spiro RH. Squamous carcinoma of the nasal cavity and paranasal sinuses. *Am J Surg*. 1989;158(4):328-332.
5. Zaharia M, Salem LE, Travezan R, et al. Postoperative radiotherapy in the management of cancer of the maxillary sinus. *Int J Radiat Oncol Biol Phys*. 1989; 17(5):967-971.
6. Paulino AC, Marks JE, Bricker P, Melian E, Reddy SP, Emami B. Results of treatment of patients with maxillary sinus carcinoma. *Cancer*. 1998;83(3):457-465.
7. Le Q-T, Fu KK, Kaplan M, Terris DJ, Fee WE, Goffinet DR. Treatment of maxillary sinus carcinoma: a comparison of the 1997 and 1977 American Joint Committee on cancer staging systems. *Cancer*. 1999;86(9):1700-1711.
8. Myers LL, Nussenbaum B, Bradford CR, Teknos TN, Esclamado RM, Wolf GT. Paranasal sinus malignancies: an 18-year single institution experience. *Laryngoscope*. 2002;112(11):1964-1969.
9. Ganly I, Patel SG, Singh B, et al. Craniofacial resection for malignant paranasal sinus tumors: report of an International Collaborative Study. *Head Neck*. 2005; 27(7):575-584.
10. Guntinas-Lichius O, Kreppel MP, Stuetzer H, Semrau R, Eckel HE, Mueller RP. Single modality and multimodality treatment of nasal and paranasal sinuses cancer: a single institution experience of 229 patients. *Eur J Surg Oncol*. 2007; 33(2):222-228.
11. Snyers A, Janssens GO, Twickler MB, et al. Malignant tumors of the nasal cavity and paranasal sinuses: long-term outcome and morbidity with emphasis on hypothalamic-pituitary deficiency. *Int J Radiat Oncol Biol Phys*. 2009;73(5):1343-1351.
12. LoRusso P, Tapazoglou E, Kish JA, et al. Chemotherapy for paranasal sinus carcinoma: a 10-year experience at Wayne State University. *Cancer*. 1988;62(1): 1-5.
13. Lee YY, Dimery IW, Van Tassel P, De Pena C, Blacklock JB, Goepfert H. Superselective intra-arterial chemotherapy of advanced paranasal sinus tumors. *Arch Otolaryngol Head Neck Surg*. 1989;115(4):503-511.
14. Rosen A, Vokes EE, Scher N, Haraf D, Weichselbaum RR, Panje WR. Locoregionally advanced paranasal sinus carcinoma: favorable survival with multimodality therapy. *Arch Otolaryngol Head Neck Surg*. 1993;119(7):743-746.
15. McCary WS, Levine PA, Cantrell RW. Preservation of the eye in the treatment of sinonasal malignant neoplasms with orbital involvement: a confirmation of the original treatise. *Arch Otolaryngol Head Neck Surg*. 1996;122(6):657-659.
16. Lee MM, Vokes EE, Rosen A, Witt ME, Weichselbaum RR, Haraf DJ. Multimodality therapy in advanced paranasal sinus carcinoma: superior long-term results. *Cancer J Sci Am*. 1999;5(4):219-223.
17. Papadimitrakopoulou VA, Ginsberg LE, Garden AS, et al. Intraarterial cisplatin with intravenous paclitaxel and ifosfamide as an organ-preservation approach in patients with paranasal sinus carcinoma. *Cancer*. 2003;98(10):2214-2223.
18. Samant S, Robbins KT, Vang M, Wan J, Robertson J. Intra-arterial cisplatin and concomitant radiation therapy followed by surgery for advanced paranasal sinus cancer. *Arch Otolaryngol Head Neck Surg*. 2004;130(8):948-955.
19. Homma A, Oridate N, Suzuki F, et al. Superselective high-dose cisplatin infusion with concomitant radiotherapy in patients with advanced cancer of the nasal cavity and paranasal sinuses: a single institution experience. *Cancer*. 2009;115 (20):4705-4714.
20. Mendenhall WM, Amdur RJ, Morris CG, et al. Carcinoma of the nasal cavity and paranasal sinuses. *Laryngoscope*. 2009;119(5):899-906.

©2011 American Medical Association. All rights reserved.
Downloaded From: http://archotol.jamanetwork.com/ on 05/19/2013